

Ag Oxysalts™

made
easy

Introduction

KerraContact™ Ag (Crawford) is an advanced wound contact dressing using Ag Oxysalts™ technology. It is the first dressing to use silver in its most chemically- and antimicrobially-active state (Lemire et al, 2015). This Made Easy outlines how Ag Oxysalts differs from other silver technologies and describes its unique mode of action, spectrum of activity, and potential role in biofilm reduction.

Authors: White R, Parker J

INFECTION AND WOUND HEALING

Infection is one of the main complicating factors in wound care. All wounds contain bacteria, but these become detrimental to healing if the wound moves from bacterial balance (organisms present but not invasive) to imbalance (critical colonisation and infection), where damage to tissue occurs (Sibbald et al, 2006). The capacity to resist bacterial invasion through the innate immune system, or 'host' response, is the single most important contributing factor.

What increases the risk of wound infections?

Infection is the result of pathogens successfully overcoming the defence strategies of a host. Diverse communities of microorganisms inhabit the outer surface of the human body, making up its normal flora. When a healthy patient has a wound, the host response effectively deals with any invading pathogens. Patients who are immuno-compromised, however, are more likely to develop an infection. The development of a wound infection is dependent on the pathogenicity and virulence of the microorganism, as well as the immuno-competency of the host (Heinzelmann, 2002).

How to recognise infection in chronic wounds

The following recommendations from The International Wound Infection Institute detail how to identify infection in chronic wounds (Swanson et al, 2015):

- **The difference between acute and chronic wounds:** the normal healing process is compromised in chronic wounds (Carville, 2012); these often share various characteristics, including impaired growth factors, increased cytokines and matrix metalloproteinases (MMPs) (Spear, 2013)
- **The infection continuum:** the relationship between wound, host, and bacteria is continuously changing based on local, environmental and systemic factors (Templeton, 2014)
- **Local versus spreading or systemic infection:** bacteria multiplying in a wound leads to localised infection, characterised by the standard signs of inflammation: pain, heat, swelling, redness and functional loss. If the infection is left untreated, bacteria may cause delayed healing, and lead to spreading or systemic infection (WUWHS, 2008)
- **Detection of biofilms:** while biofilms can delay wound healing, a routine laboratory test for their detection has not yet been established (Fazli, 2009)
- **Wound culture does not diagnose infection:** diagnosis relies largely on assessing signs and symptoms of infection; reasons to seek laboratory assistance include failure of antimicrobial intervention, the need to identify a particular pathogen (such as MRSA), or failure to heal (Swanson et al, 2015)
- **Recognition of alternative diagnostics:** a normal culture will not indicate presence of biofilm. New point-of-care diagnostic techniques can indicate that a wound is high in harmful proteases, which may demonstrate chronic inflammation that is often associated with biofilm (Izzo et al, 2014).

Assessment of wounds for infection should involve a full evaluation of the patient, taking into account wound aetiology, comorbidities and immune status, and how these affect risk and severity of infection (WUWHS, 2008). Clinicians should maintain a high index of suspicion in patients with chronic wounds, looking out for characteristic signs of infection, as shown in Figure 1.

How do biofilms delay healing?

After attaching to a surface such as a wound bed, bacteria can encase themselves in a gelatinous matrix known as a biofilm. These complex microbial communities can contain numerous bacterial

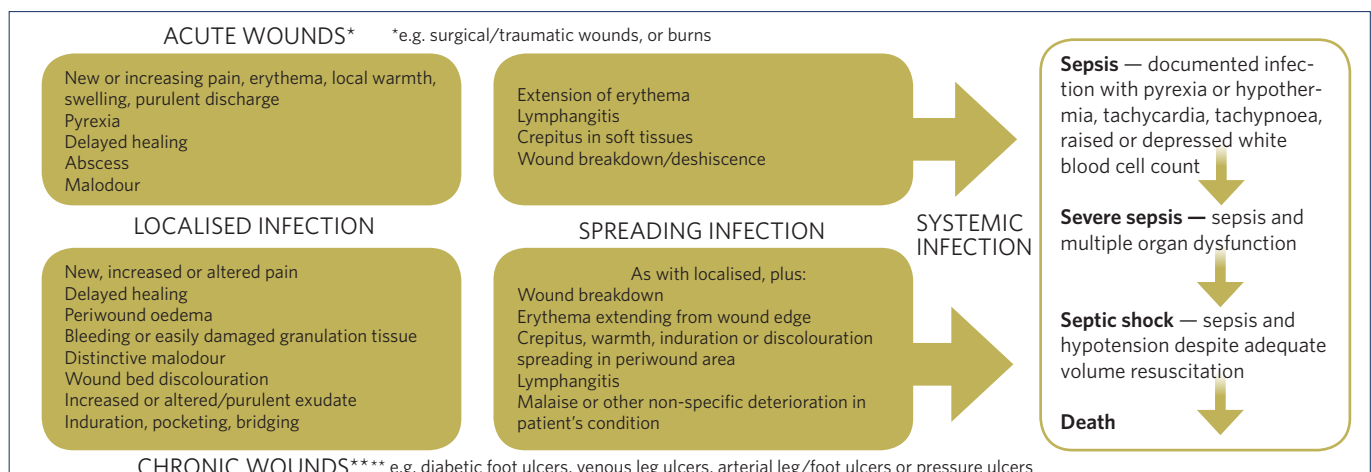


Figure 1: Acute versus chronic wound infection (adapted from WUWHS, 2008)

species, protected against the immune system and antimicrobial agents (WUWHS, 2008). Biofilms cause a chronic inflammatory response in acute wounds that results in an abundance of neutrophils and macrophages that secrete high levels of reactive oxygen species, proteases (MMPs), and elastase (Phillips, 2010). These help break down the attachments between the biofilm and wound tissue, dislodging the biofilm from the wound (EWMA, 2004).

However, in chronic wounds, biofilms are suspected to delay wound healing (James et al, 2008), because the response is not always successful in removing the biofilm. It is thought that this response may perpetuate rather than eliminate the biofilm, inducing an ineffective inflammatory response (Lawrence et al, 2007).

What is the role of silver in infection management?

Silver, in its metallic form (Ag^0), is unreactive and does not kill bacteria. To become bactericidal, silver atoms must lose an electron and become positively charged silver ions. Silver ions are highly reactive, affecting multiple sites in bacterial cells. They ultimately cause cell death by binding to bacterial cell membranes and causing disruption of the cell wall and cell leakage (Lansdown, 2002).

A number of silver dressings are available, with broad-spectrum antimicrobial activity that reduce bioburden and combat wound infection (Edwards-Jones, 2009; Carter et al, 2010; Toy and Macera, 2011; Aziz et al, 2012; Politano et al, 2013). In this respect, silver dressings have proven to be very effective (White et al, 2006; Leaper, 2006; Lo et al, 2009; Lipsky and Hoey, 2009). The advantages of topical antiseptics such as silver (antimicrobial agents that kill, inhibit or reduce the number of microorganisms present) over antibiotics are numerous. For example: localised antimicrobial wound therapy as opposed to whole body systemic exposure; immediate access to the wound bed in bactericidal concentration (even in the ischaemic limb); and antibiofilm activity.

Judicious use of topical antimicrobials plays a vital role in tackling wound bioburden and biofilm (Lipsky and Hoey, 2009). Moreover, the anti-biofilm activity of topical agents has been reviewed *in vitro* and silver is attributed with this advantage (Chung and Toh, 2014). This is an important distinction for chronic wounds where biofilm formation is strongly implicated in chronicity and recalcitrance (Cooper et al, 2014).

Evidence suggests an initial 2-week trial of treatment before the approach is re-evaluated, sometimes known as the '2-week challenge'. During this time, the efficacy of the silver dressing can be assessed, after which a decision can be made on whether to continue or discontinue its use (Wounds International, 2012; Dowsett 2014).

UNDERSTANDING AG OXSALTS

Ag Oxsalts is a unique silver technology that is bactericidal, disrupts biofilms and prevents their reformation while also being cost-effective and patient-friendly (Crawford Healthcare, 2015).

Why is Ag Oxsalts technology particularly effective at killing bacteria?

Silver is only effective at killing bacteria when it is missing electrons and in its ionic state. The more electrons are missing, the more reactive it becomes and the greater its ability to disrupt the normal function of bacteria. Dressings with Ag Oxsalts technology are particularly effective at killing bacteria since they are designed with three electrons missing (Ag^{3+}), compared with other silver dressings that are only missing one electron (Ag^+) (Figure 2) (Spina C, Crawford Healthcare, Data on File).

Evidence for use of Ag Oxsalts technology

Evidence for Ag Oxsalts technology derives from a number of studies, including a 50-patient multicentre study, a 20-patient case series, two *in vitro* studies, and an *in vivo* model (Table 1). Ag Oxsalts has been evaluated in terms of presence of infection indicators, antimicrobial activity, speed of kill, biofilm activity and pain reduction.

Fast and effective at killing bacteria

Ag Oxsalts technology is proven to quickly kill 99.999% of a broad spectrum of bacteria (Crawford Healthcare, 2015) (Box 1).

Table 1. Evidence for Ag Oxsalts technology

Effective antimicrobial activity In an <i>in vitro</i> study, Ag Oxsalts was effective against all of the tested wound pathogens	Lemire et al, 2015
Clinically effective in just 7 days In a 50-patient multicentre study, a dramatic response was seen within 7 days	Motta et al, 2012
Fast speed of kill In an <i>in vitro</i> study with known wound pathogens, a log 4 reduction was achieved in 4 hours or less (in a simulated wound fluid [SWF]), with a sustained effect over 7 days	Lemire et al, 2015
Effective against biofilms In an <i>in vitro</i> study, organisms were grown in the Calgary biofilm device using peptone or SWF. The Ag Oxsalts dressing gave a log 7 reduction for both 24-hour and 72-hour biofilms	Miller et al, 2013
Progression to healing Of 50 patients, 45% went on to heal within an average of 2.9 weeks	Motta et al, 2012
Reduced wound size In a 20-patient case series of patients with chronic foot (n=10) or leg (n=10) ulcers, wound size reduced over an 8-week period for 16 stalled wounds with localised infection	Sibbald R et al, 2012
Reduced pain In a 20-patient case series, pain scores reduced dramatically over treatment (cumulative pain scores: week 0=44.5; week 8=33) In a 50-patient multicentre study, 93% of patients reported reduced wound pain, with no pain at dressing application and removal	Sibbald R et al, 2012; Motta et al, 2012
Patient comfort The Ag Oxsalts dressing demonstrated only a nominal shift in pH (pH levels are altered by increased bacterial load, which can cause irritation and pain), at a markedly lower silver concentration compared with most competitors; patients experienced minimal pain with increased comfort, without compromise on biocidal effectiveness In a 50-patient multicentre study, clinicians observed null or minimal staining, and the dressing was considered safe and gentle for various wound aetiologies	Exciton Technologies, 2009; Motta et al, 2012

Box 1: Ag Oxysalts technology is effective against:

Gram-negative

- *Acinetobacter baumannii*
- *Escherichia coli*
- *Pseudomonas aeruginosa*
- *Klebsiella pneumoniae*

Gram-positive

- *Corynebacterium striatum*
- *Enterococcus faecalis*
- *Enterococcus faecalis VRE*
- *Staphylococcus epidermidis*
- *Staphylococcus aureus*
- Methicillin-resistant *staphylococcus aureus*

Fungus

- *Candida albicans*
- *Aspergillus niger*

Destroys biofilms

Ag Oxysalts disrupts and breaks down the biofilm, exposing bacteria to be killed. In an *in vitro* study, mature biofilms of *Pseudomonas aeruginosa* and *Staphylococcus aureus* were grown and treated. No viable bacteria was retrieved after 24 hours. The biofilms had been disrupted allowing the bacteria to be killed quickly and effectively (Miller et al, 2013).

WHAT IS KERRACONTACT AG?

KerraContact Ag is a unique silver wound dressing that utilises Ag Oxysalts technology, which acts quickly (within 1 week) against bacteria and destroys biofilms. This speed of response means that instead of aiming for a '2-week challenge', clinicians can assess wounds for reduction in the signs and symptoms of infection after just 1 week. KerraContact Ag has also proven safe and gentle for patients with wounds of various aetiologies.

The composition and properties of KerraContact Ag are shown in Figure 3.

Indications for use

KerraContact Ag can be used for acute and chronic wounds that are locally infected or at high risk of infection, including burns, leg ulcers, pressure ulcers, diabetic foot ulcers, and surgical wounds (Crawford Healthcare, 2015). Also, in the stage between colonisation and infection referred to as critical colonisation or localised infection (WUWHHS, 2008), the use of an antimicrobial dressing such as KerraContact Ag should be considered (Wounds UK, 2013). KerraContact Ag can also be used immediately following debridement if a biofilm is suspected (Dowsett, 2013).

The case study on page 4 highlights the benefits of using KerraContact Ag in a patient with a chronic venous leg ulcer.

How to apply KerraContact Ag

If KerraContact Ag is indicated, it can be used on any type of wound following a detailed holistic assessment, unless there is a known allergy to any of its ingredients. KerraContact Ag can be applied directly to the wound bed. The silver does not need to be activated in any way (i.e. it does not need to be moistened). It can be cut to wound size and shape. A secondary dressing will be indicated in the majority of cases. The dressing will need to be changed as often as clinical assessment suggests at each dressing change, but can be left *in situ* for up to 7 days.

Figure 2: Increased effectiveness of Ag Oxysalts technology

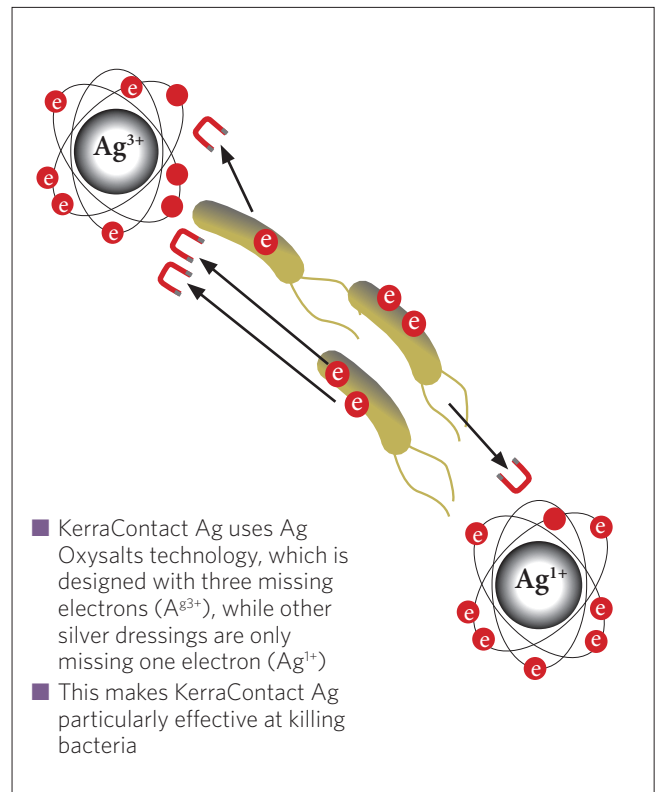
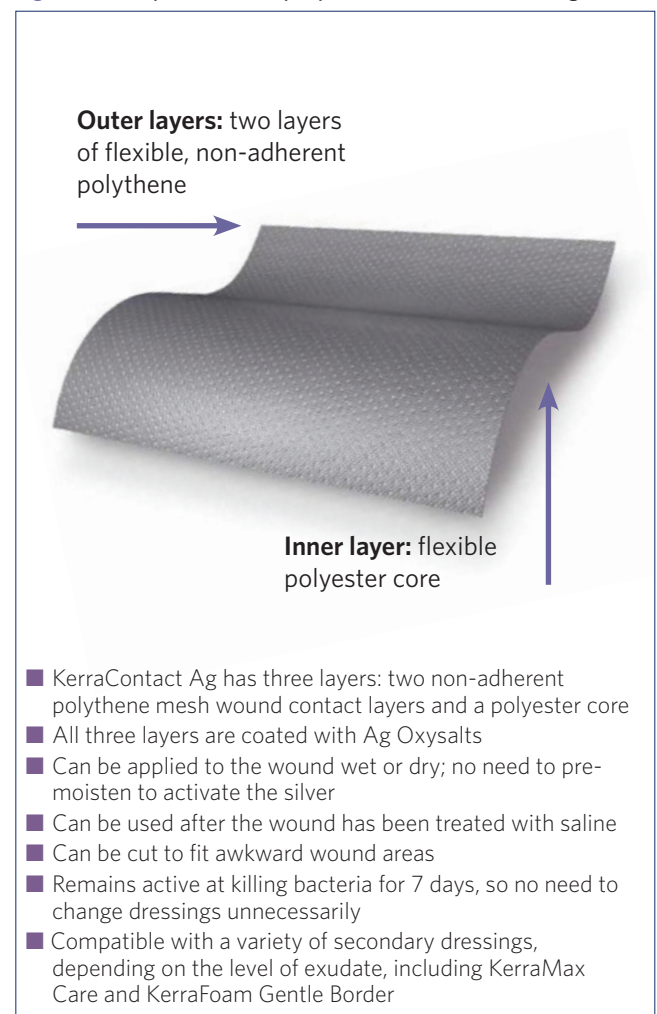


Figure 3: Composition and properties of KerraContact Ag



CASE STUDY (Clinician: Rachel Parker)

A 79-year-old female presented with a 4-year history of bilateral venous leg ulcers. Both legs were ulcerated from the toe to the knee, with a high level of exudate, pain at dressing change, and malodour. Her wounds were infected (MRSA and *Pseudomonas aeruginosa*). She had a history of myocardial infarction, arthritis, and osteoporosis.

Treatment

The patient was treated with KerraContact Ag for 7 days, with the aim of treating the infection, with KerraMax Care used as a secondary dressing.

Outcomes

After 7 days, the wound appeared drier, cleaner and less inflamed, and the surrounding erythema had reduced. Reductions were seen in levels of exudate (significant reduction), odour, and swelling, heat and redness (slight reduction). KerraContact Ag was rated 4 out of 5 for overall improvement in the condition of the wound. The patient reported that KerraContact Ag was extremely easy to apply and remove. Fewer dressing changes were required compared with previous treatment, reducing the discomfort of dressing change.

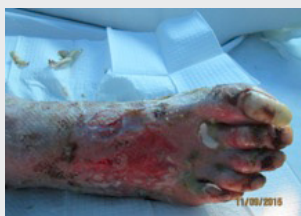

Figure 1: On presentation, prior to the use of KerraContact Ag

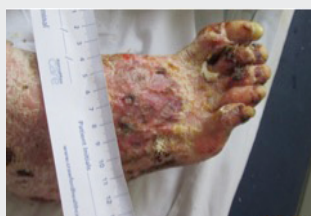

Figure 2: 7 days after commencing treatment with KerraContact Ag

REFERENCES

- Aziz Z, Abu SF, Chong NJ (2012) A systematic review of silver-containing dressings and topical silver agents (used with dressings) for burn wounds. *Burns* 38(3): 307-18
- Carter MJ, Tingley-Kelley K, Warriner RA 3rd (2010) Silver treatments and silver-impregnated dressings for the healing of leg wounds and ulcers: a systematic review and meta-analysis. *J Am Acad Dermatol* 63(4): 668-79
- Carville K (2012) Wound Care Manual. Silver Chain Foundation. Osborne Park, WA
- Chung PY, Toh YS (2014) Anti-biofilm agents: recent breakthrough against multi-drug resistant *Staphylococcus aureus*. *Pathog Dis* 70(3): 231-9
- Cooper RA, Bjarnsholt T, Alhede M (2014) Biofilms in wounds: a review of present knowledge. *J Wound Care* 23(11): 570-80
- Crawford Healthcare (2015) Introducing the world's most advanced silver dressing <http://www.crawfordhealthcare.com/woundcare/kerracontact-ag/> (accessed on 30.10.15)
- Dowsett C (2013) Biofilms: a practice-based approach to identification and treatment. *Wounds UK* 9(2): 68-72
- Dowsett C (2014) Adopting the 2-week challenge in practice: making the case for silver dressings. *Wounds UK* 10(2): 80-5
- Edwards-Jones V (2009) The benefits of silver in hygiene, personal care and healthcare. *Lett Appl Microbiol* 49(2): 147-52
- European Wound Management Association (EWMA) (2004) Position Document: *Wound Bed Preparation in Practice*. London: MEP Ltd
- Exciton Technologies (2009) In vitro Cytotoxicity Evaluation: Mammalian Fibroblast Cells. Data on File.
- Fazli M, Bjarnsholt T, Kirketerp-Møller K, et al (2009) Non-random distribution of *Pseudomonas aeruginosa* and *Staphylococcus aureus* in chronic wounds. *J Clin Microbiol* 47(12): 4084-9
- Heinzelmann M, Scott M, Lam T (2002) Factors predisposing to bacterial invasion and infection. *Am J Surg* 183(2): 179-90

Izzo V, Meloni M, Vainieri E, et al (2014) High matrix metalloproteinase levels are associated with dermal graft failure in diabetic foot ulcers. *Int J Low Extrem Wounds* 13: 191-6

James GA, Swogger E, Wolcott R et al (2008) Biofilms in chronic wounds. *Wound Repair Regen* 16(1): 37-44

Lansdown AB (2002) Silver. I: Its antibacterial properties and mechanism of action. *J Wound Care* 11(4): 125-30

Lawrence JR, Swerhone GD, Kuhlicke U, Neu TR (2007) *In situ* evidence for microdomains in the polymer matrix of bacterial microcolonies. *Can J Microbiol* 53(3): 450-58

Leaper DJ (2006) Silver dressings: their role in wound management. *Int J Wound* 3(4): 282-94

Lemire JA, Kalan L, Bradu A, Turner RJ (2015) Silver oxynitrate, an unexplored silver compound with antimicrobial and antibiofilm activity. *Antimicrob Agents Chemother* 59(7):4031-9

Lipsky BA, Hoey C (2009) Topical antimicrobial therapy for treating chronic wounds *Clin Infect Dis* 49(10): 1541-9

Lo SF, Chang CJ, Hu WY, et al (2009) The effectiveness of silver-releasing dressings in the management of non-healing chronic wounds: a meta-analysis. *J Clin Nurs* 18(5): 716-28

Miller S, Lemire J, Branbu A, Ul-Haq I, Lischuk D, Spina C, Turner R, Kalan L (2013) Antimicrobial silver in medical devices: Composition and efficacy. Poster presented at: Spring meeting of Symposia on Advanced Wound Care. May, Denver, CO

Motta G, Merkle D, Milne C, et al (2012) Multi-Center Prospective Clinical Evaluation and Cost Analysis of a New Silver dressing. Poster presented at: SAWC

Politano AD, Campbell KT, Rosenberger LH, Sawyer RG (2013) Use of silver in the prevention and treatment of infections: silver review. *Surg Infect (Larchmt)* 14(1): 8-20

Phillips PL, Wolcott RD, Fletcher J, Schultz GS (2010) Biofilms Made Easy. *Wounds International* 1(3): Available from <http://www.woundsinternational.com>

Sibbald RG, Woo K, Ayello EA (2006) Increased bacterial burden and infection: the story of NERDS and STONES. *Adv Skin Wound Care* 19(8):447-61

Sibbald RG, Goodman L, Woo KY, Smart H, Tariq G, et al (2011) Special considerations in wound bed preparation: an update. *Adv Wound Care* 24: 415-436

Spina C. Silver I, II, III: Chemical Characteristics, Properties, and Anti-microbial Activity. Data on File. Crawford Healthcare Ltd

Spear M (2013) Acute or chronic? What's the difference? *Plast Surg Nurs* 33(2): 98-100

Swanson T, Keast D, Cooper R, et al (2015) Ten top tips: identification of wound infection in a chronic wound. *Wounds International* 6(2): 22-7

Templeton S. Infected wounds. In: Swanson T, Asimus M, McGuinness W (eds) (2014) *Wound Management for the Advanced Practitioner*. IP Communications, Melbourne, Australia

Toy LW, Macera L (2011) Evidence-based review of silver dressing use on chronic wounds. *J Am Acad Nurse Pract* 23(4): 183-92

White RJ, Cutting KF, Kingsley AR (2006) Topical antimicrobials in the control of wound bioburden. *Ostomy Wound Manag* 52(8): 26-59

World Union of Wound Healing Societies (WUWHS) (2008) Principles of best practice: Wounds infection in clinical practice. An international consensus. London: MEP Ltd. Available from: www.woundsinternational.com

Wounds UK (2013) Best Practice Statement: The use of Topical Antimicrobial Agents in Wound Management (3rd edition), London

AUTHOR DETAILS White R¹, Parker J²

1. *Clinical Editor, Wounds UK; Professor of Tissue Viability, University of Worcester and Director of Plymouth Wound Care*
2. *Tissue Viability Lead Specialist Nurse, The Queen Elizabeth Hospital King's Lynn NHS Foundation Trust*

KerraContact Ag is a registered trademark of Crawford Healthcare. KerraContact,™ KerraMax Care™ and KerraFoam™ are trademarks of Crawford Woundcare Ltd. Ag Oxyalts™ is a trademark of Exciton Technologies.